



## PATIENT

Edward Simon

## SPECIES

Feline

## BREED

DSH

## SEX

Male Neutered

## AGE

3 years

## WEIGHT

13.6lbs

## INTERPRETED BY

Maggie Machen Lamy,  
DVM, DACVIM  
(Cardiology)

## IMAGING PERFORMED BY

Kelly Vazquez, CVT

## HOSPITAL NAME

NorthvaleVeterinary  
Clinic

## REFERRING VET

Dr. Simon

## INVOICE

28824

## DATE

2/7/23

## PRESENTING CLINICAL SIGNS

History: Presented for likely feline asthma; wheezing attacks twice daily with no definitive causation. No current meds.

-Abnormal PE/Chem/CBC/UA Results: Mild lymphocytosis and neutropenia.

## ECHOCARDIOGRAM FINDINGS

2D, m-mode, color flow and doppler imaging is available. The left ventricular wall is asymmetric with a borderline septal thickening. The remainder of the LV wall measures normal. There is a mildly hyperechoic endocardium consistent with fibrosis. The papillary muscles are mildly remodeled and hyperechoic. The left atrium is normal in size. The right atrium is normal in size. The right ventricle appears normal. The mitral valve is normal in structure and mobility. No MR. No TR. Blood flow through the RVOT and LVOT is normal in velocity. No pleural or pericardial effusion seen. No obvious cardiac tumors.

## CARDIAC CHART

FELINE CARDIAC PARAMETERS	BODY WEIGHT (kg)	HR (BPM)	IVSd (cm) <small>(Moise, Pipers)</small>	LVIDd (cm) <small>(Moise, Pipers)</small>	LVWd (cm) <small>(Moise, Pipers)</small>	FS (%)	EF (%)
NORMAL PARAMETER	-----	150-240	0.35-0.55	<2 (mean 1.5)	3.5-0.55	35-67	80-100
PATIENT	6.2	167	0.57	1.3	0.47	49	84
FELINE CARDIAC PARAMETERS	LA/AO <small>(Boon)</small>	LA/AO HEART BASE (Swe) <small>(Abbott)</small>	LA 2D short axis Base view (cm) <small>(Abbott)</small>		LVOT VEL <small>(m/s)</small>	RVOT VEL <small>(m/s)</small>	E max <small>(m/s)</small>
NORMAL	<1.5	<1.3	<1.2		<1.6	<1.3	<0.9
PATIENT	1.4	1.2	1.1		0.9	0.8	NM

*\*Note: All measurements based upon multi-modal images and methods. An average value is reported.  
Adapted from June Boon, Veterinary Echocardiography, 1998  
Abbott J & MacLean H JVIM 2006;20: 111-119, Moise et al. Am J Vet Res 47:1476, 1986. Pipers et al. Am J Vet Res 40:882, 1979.*

## INTERPRETATION OF THE FINDINGS & FURTHER RECOMMENDATIONS

Overtly normal cardiac dimensions and function. The only abnormality identified is a borderline focal septal thickening, which may be indicative of early hypertrophic disease or may simply represent a normal variant. Regardless, the LA remains normal which would indicate clinical stability. Serial echocardiography will be necessary to determine progression and clinical significance. Monitor BP/T4 every 6-12 months.

With a normal LA dimension, no medications are indicated. Prognosis is open pending assessing for progression.

Given these findings, anesthetic risk is mild, however any cat with this degree of fibrosis and diastolic dysfunction will be at risk for iatrogenic IV fluid overload should they be needed in the future. Risk for steroid use typically follows atrial enlargement, which in this case is low. That being said, any cat can develop acute intolerance and monitoring of RR/RE is recommended, particularly during the initiation phase.



**PATIENT**

Edward Simon

Monitor for any development of clinical signs, including labored breathing or signs of a blood clot (paralysis, neurologic change).

**SPECIES**

Feline

A recheck echocardiogram is recommended in 6-12 months to screen for any progressive changes.

**BREED**

DSH

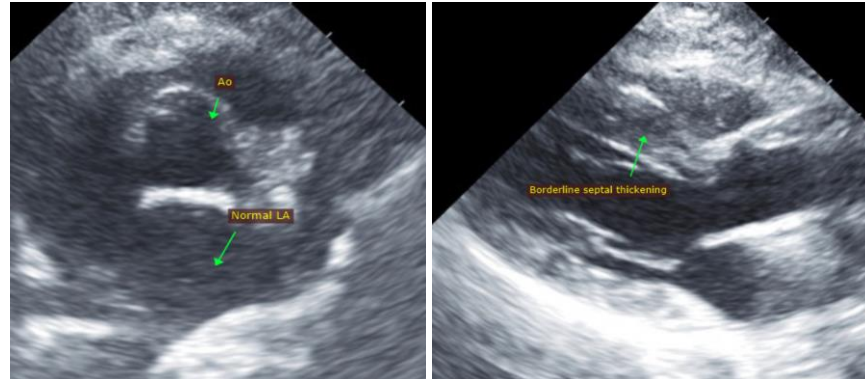
**SEX**

Male Neutered

**AGE**

3 years

**IMAGES**



**WEIGHT**

13.6lbs

The information and recommendations provided are based on the images presented by the referring veterinarian. No evaluation can be communicated regarding pathology that was not visible in the image/video clips provided.

**INTERPRETED BY**

Maggie Machen Lamy,  
DVM, DACVIM  
(Cardiology)

Thank you for this referral. This report was generated using transcription software, and minor dictation errors may be present. If the clinical or image interpretation does not parallel your findings or if I can be of any further assistance, please contact me.

**Maggie Machen Lamy, DVM**  
Diplomate of the American College of Veterinary Internal Medicine (Cardiology)  
info@sonopath.com

**IMAGING PERFORMED BY**

Kelly Vazquez, CVT

**HOSPITAL NAME**

NorthvaleVeterinary  
Clinic

**REFERRING VET**

Dr. Simon

**INVOICE**

28824

**DATE**

2/7/23